

Short Communication

Neuronal apoptosis in immunodeficient mice infected with the challenge virus standard strain of rabies virus by intracerebral inoculation

Maegan Rutherford¹ and Alan C Jackson^{1,2}

Departments of ¹Microbiology and Immunology and ²Medicine, Queen's University, Kingston, Ontario, Canada

The challenge virus standard-11 strain (CVS) of fixed rabies virus produces neuronal apoptosis in widespread areas of the brain of mice after intracerebral inoculation. The role of the adaptive immune response in producing neuronal apoptosis in this model was evaluated by comparing the infections in adult C57BL/6J mice with nude mice (T cell deficient) and *Rag1* mice (T and B cell deficient). Both strains of immunodeficient mice showed very similar clinical disease and neuropathological findings, including marked neuronal apoptosis. The adaptive immune response is unlikely of fundamental importance in producing neuronal apoptosis in the brains of mice in this model. *Journal of NeuroVirology* (2004) 10, 409–413.

Keywords: neuronal apoptosis; rabies; viral pathogenesis

An understanding of rabies pathogenesis will likely be important in the development of novel therapies for rabies encephalitis, which is a fatal disease in humans (Jackson, 2002a, 2002b; Jackson *et al*, 2003). Neurotropic viruses may cause neuronal cell death by either apoptosis or necrosis (Griffin and Hardwick, 1999; Allsopp and Fazakerley, 2000; Fazakerley and Allsopp, 2001). Apoptosis depends on synthesis of macromolecules and requires energy, whereas, in contrast, necrosis is associated with energy failure (Friedlander, 2003). The destruction of infected cells by apoptosis has been proposed as an innate host cellular response that acts to limit viral propagation during infection (Alcami and Koszinowski, 2000). The challenge virus standard-11 strain (CVS) of fixed rabies virus has been observed to induce apop-

totic cell death in rat prostatic adenocarcinoma cells (Jackson and Rossiter, 1997), mouse neuroblastoma cells (Theerasurakarn and Ubol, 1998), and in mouse embryonic hippocampal neurons (Morimoto *et al*, 1999), although only limited apoptosis is produced in human neuroblastoma SK-N-SH and lymphoblastoid Jurkat T-cell lines (Thoulouze *et al*, 1997, 2003; Prehaud *et al*, 2003). CVS and other lyssaviruses have been shown to induce caspase dependent apoptosis in mouse neuroblastoma cells (Ubol *et al*, 1998; Kassis *et al*, 2004). Rabies encephalitis in adult, suckling, and neonatal mice inoculated intracerebrally with CVS is associated with marked neuronal apoptosis in multiple brain regions (Jackson and Rossiter, 1997; Jackson and Park, 1998; Theerasurakarn and Ubol, 1998). In contrast, adult animals infected with CVS by peripheral routes of inoculation demonstrate severe and fatal encephalitis without prominent neuronal apoptosis (Reid and Jackson, 2001; Jackson, 2003), and CD3-positive T cells are the main contributor to the pool of apoptotic cells in central nervous system (CNS) tissues (Baloul and Lafon, 2003). Morimoto *et al* (1999) have observed that CVS variants that are more neurovirulent in adult mice produce less apoptosis *in vitro* over a period of 72 h in primary hippocampal neurons than produced by less neurovirulent variants. Lafon and coworkers have shown that intramuscular inoculation in the hindlimbs of mice with the Pasteur strain of rabies

Address correspondence to Dr. Alan C. Jackson, Kingston General Hospital, Connell 725, 76 Stuart Street, Kingston, ON K7L 2V7, Canada. E-mail: jacksona@post.queensu.ca

The authors are grateful for technical assistance from Pamini Rasalingam, statistical advice from Dr. Miu Lam (Department of Community Health and Epidemiology, Queen's University), and for the gift of monoclonal antibody 5DF12 from Dr. Alexander I. Wandeler (Centre for Rabies Expertise, Canadian Food Inspection Agency, Nepean, Ontario). This work was supported by Canadian Institutes of Health Research grant MOP-64376 and the Queen's University Violet E. Powell Research Fund (both to A.C. Jackson).

Received 22 April 2004; revised 14 June 2004; accepted 6 August 2004.

virus (PV) produces local and irreversible paralysis of the inoculated limbs that is associated with infected neurons in the spinal cord that undergo apoptotic cell death (Galelli *et al.*, 2000). Furthermore, they noted that PV-infected nude mice did not develop paralysis or neuronal apoptosis, although these mice succumbed from fatal infection. These observations have indicated that neuronal apoptosis in this abortive model is likely controlled by the immune response with a T cell-dependent immune response triggered by PV. In contrast, peripheral inoculation of CVS was not observed to be associated with T cell-mediated apoptosis, and there is evidence that this occurs as a result of virus-induced stimulation of cell death in migrating T cells and secretion of neuroprotective factors, including interleukin (IL)-6, which limits inflammation (Baloul and Lafon, 2003). These “protective” measures allow preservation of neuronal integrity and the neuronal network, resulting in successful propagation of CVS infection in the CNS with a fatal outcome.

The role of the immune response in the neuronal apoptosis associated with intracerebral inoculation of CVS has not been studied in detail, although it has been reported that the brains of CVS-infected immunosuppressed mice demonstrated massive apoptosis (Theerasurakarn and Ubol, 1998). We have studied CVS infection of immunodeficient mice, including both nude mice (T cell deficient) and *Rag1* mice (T and B cell deficient) (Mombaerts *et al.*, 1992) and compared the infec-

tions with CVS-infected syngeneic immunocompetent mice in order to explore the role of the adaptive immune response in producing the apoptotic neuronal death in the brain in this model.

Five-and-a-half-week-old female *Rag1* C57BL/6J mice (stock no. 002216, The Jackson Laboratory, Bar Harbor, ME), nude C57BL/6J mice (stock no. 000819, The Jackson Laboratory), and C57BL/6J mice (The Jackson Laboratory) were inoculated intracerebrally with a dose of 857 plaque-forming units of CVS in 0.03 ml. All C57BL/6J mice and *Rag1* mice developed signs of clinical rabies on 7 to 8 days post infection (p.i.). The mice became hunched and slow and developed limb paralysis. They were killed on days 8 to 10 p.i. when their neurologic disease became severe. Clinical signs developed 1 day later in five of eight (63%) nude mice than in C57BL/6J mice and in *Rag1* mice, but progression was quicker and severe disease occurred at the same time.

Mice were killed after they developed severe neurologic signs between 8 and 10 days p.i. Brain tissues were fixed in buffered 4% paraformaldehyde and embedded in paraffin. Histopathologic changes were evaluated on cresyl violet-stained tissue sections. Morphologic changes in neurons included multiple condensations of nuclear chromatin and cytoplasmic shrinkage. Apoptotic neurons were widely distributed in the brain, but changes were most marked in pyramidal neurons of the hippocampus and in neurons in deep cerebellar nuclei (Figure 1). There was a variable amount of associated

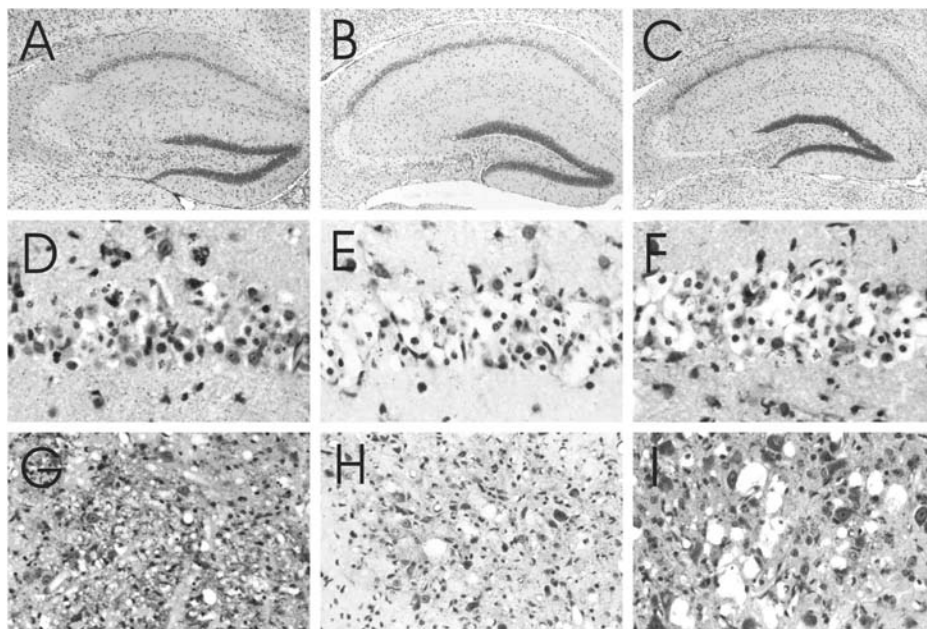


Figure 1 Hippocampus (A–C) and pyramidal neurons of the hippocampus (CA1 region) (D–F) in CVS-infected C57BL/6J mouse (A, D), nude mouse (B, E), and *Rag1* mouse (C, F) on day 8 or 9 p.i. All mice show loss of pyramidal neurons in the CA3 region (A–C). The CA1 region shows neuronal loss, nuclear condensations of chromatin, and cytoplasmic shrinkage (D–F) in all mice. Deep cerebellar nuclei of CVS-infected C57BL/6J mouse (G), nude mouse (H), and *Rag1* mouse (I) days 8 to 10 p.i. showing loss of neurons, apoptotic nuclear changes, and severe vacuolation in all mice. Cresyl violet staining. A–C, $\times 30$; D–F, $\times 270$; G–I, $\times 170$.

Table 1 Morphological changes in apoptotic neurons

Brain region	C57BL/6J mice (n = 14)	Nude mice (n = 8)	Rag1 mice (n = 8)	Significance
Cerebral cortex	2.69 ± 0.46	2.19 ± 0.26	2.25 ± 0.46	$P > .05$ (NS)
Hippocampus: CA1 region	3.50 ± 0.58	3.83 ± 0.26	3.88 ± 0.23	$P > .05$ (NS)
Hippocampus: CA3 region	4.00 ± 0	4.00 ± 0	4.00 ± 0	$P > .05$ (NS)
Cerebellum: Purkinje cells	3.25 ± 0.46	3.13 ± 0.52	3.00 ± 0.76	$P > .05$ (NS)
Cerebellum: deep cerebellar nuclei	3.63 ± 0.44	3.00 ± 0.29	3.13 ± 0.52	$P > .05$ (NS)
Midbrain tegmentum	2.38 ± 0.23	2.25 ± 0.27	2.13 ± 0.23	$P > .05$ (NS)

Morphological changes of apoptosis were evaluated in neurons in the cerebral cortex, hippocampus (CA1 and CA3 regions), cerebellum (deep cerebellar nuclei and Purkinje cells), and midbrain under high magnification (40× objective). A semiquantitative evaluation of the severity of apoptotic changes was performed twice and the identity of all slides was masked during scoring in order to prevent bias in the evaluation. Rating scale scores are expressed as the mean score ± standard deviation: 0, no significant changes; 1, mild changes; 2, moderate changes; 3, severe changes; 4, very severe changes or neuronal loss. Statistical significance was evaluated with a nonparametric, one-way ANOVA analysis using Bonferroni's multiple test comparison with a confidence level of 95% for significance ($P < .05$) (Rosner, 1995). NS, not significant.

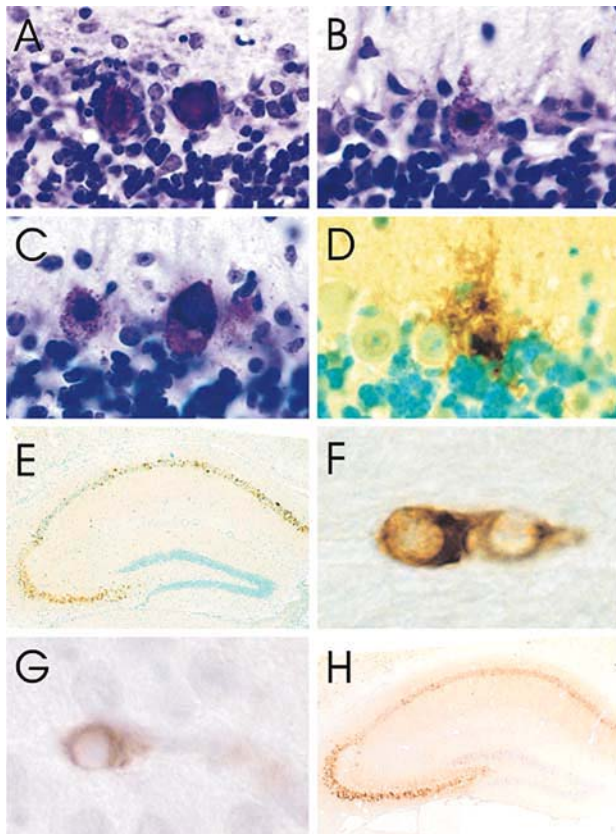


Figure 2 Cerebelli of CVS-infected C57BL/6J mouse (A), nude mouse (B), and *Rag1* mouse (C) days 8 to 10 p.i. showing marked degeneration of Purkinje cells with mineralization in all mice. TUNEL staining in a CVS-infected C57BL/6J mouse on day 9 p.i. showing signal in a Purkinje cell (D) and in a CVS-infected *Rag1* mouse day 9 p.i. showing signal in pyramidal neurons of the hippocampus (E). Immunoperoxidase staining for activated caspase-3 in CVS-infected nude mice on day 8 p.i. showing signal in neurons in a deep cerebellar nucleus (F) and in the pyriform cortex (G). Immunoperoxidase staining for rabies virus antigen in the hippocampus (H) of a CVS-infected C57BL/6J mouse showing extensive staining in pyramidal neurons of the hippocampus and mild staining of neurons in the dentate gyrus. A–C, Cresyl violet staining; D, E, TUNEL staining with methyl green counterstaining; F–H, immunoperoxidase-hematoxylin. A–C, ×720; D, ×580; E, ×40; F, ×2400; G, ×1900; H, ×35.

mineralization in deep cerebellar nuclei. Moderate changes were also noted in neurons in the cerebral cortex, diencephalon, and brainstem, and also in occasional Purkinje cells (Figure 2A to C). Mineralization was also noted in Purkinje cells with degenerative changes. Infiltration of mononuclear inflammatory cells was observed in the leptomeninges, perivascular regions, and in the brain parenchyma of the C57BL/6J mice, but not in the brains of either nude mice or *Rag1* mice. Activated microglial cells were noted in the brains of all of the CVS-infected mice. There was no significant difference in the severity or distribution of the apoptotic neuronal changes in the C57BL/6J mice, nude mice, and *Rag1* mice (Table 1).

Oligonucleosomal DNA fragmentation was assessed *in situ* in sections using the terminal deoxynucleotidyl transferase-mediated dUTP-biotin nick-end labeling (TUNEL) method using a TdT-FragEL DNA fragmentation detection kit (catalog no. QIA33) (Oncogene Research Products, San Diego, CA). Positive TUNEL staining was observed in widespread brain neurons with morphologic changes of apoptosis, including Purkinje cells (Figure 2D) and hippocampal (Figure 2E) and cortical neurons. Immunohistochemical staining for cleaved (activated) caspase-3 (Asp175) (Cell Signaling Technology, Beverly, MA) was observed in neurons in brain regions of mice with apoptotic neuronal changes (Figure 2F and G). However, the numbers of neurons that demonstrated staining for activated caspase-3 were much smaller than the numbers of neurons showing morphologic changes of apoptosis and positive TUNEL staining, and also considerably less than for immunohistochemical staining for activated caspase-3 in suckling mice infected by intracerebral inoculation with the SAD-L16 strain of fixed rabies virus (P. Rasalingam and A.C. Jackson, unpublished observations). Hence, there is uncertainty about to what extent neuronal apoptosis involves caspase-dependent pathways in this model.

Tissue sections were stained for rabies virus antigen by the avidin-biotin-peroxidase complex

method using monoclonal mouse anti-rabies virus immunoglobulin G (IgG) 5DF12 primary antibody (obtained from Alexander I. Wandeler, Centre of Expertise for Rabies, Canadian Food Inspection Agency, Nepean, Ontario) as previously described (Jackson *et al.*, 1999).

Rabies virus antigen was widely distributed in neurons throughout the brains of all of the CVS-infected mice, which had severe disease. Infection was prominently noted in the pyramidal neurons of the hippocampus (Figure 2H) and neurons in the brainstem, cerebellum (deep cerebellar nuclei and Purkinje cells), and cerebral cortex. Neurons were also noted to be infected in the dentate gyrus of the hippocampus. C57BL/6J mice, nude mice, and *Rag1* mice exhibited similar amounts and similar distributions of rabies virus antigen in the brain (data not shown).

Intracerebral inoculation of CVS in adult C57BL/6J mice resulted in a severe encephalitis associated with widespread neuronal apoptosis in multiple brain areas. The present study of CVS infection in adult C57BL/6J mice showed similar findings as in previous studies of CVS infection in adult ICR mice (Jackson and Rossiter, 1997). However, there were some differences, including apoptosis of occasional infected Purkinje cells and infection of neurons in the dentate gyrus of the hippocampus in the C57BL/6J mice. Nude mice and *Rag1* mice are useful tools in assessing the role of the adaptive immune response in producing CVS-induced neuronal apoptosis. Both CVS-infected nude mice and *Rag1* mice demonstrated widespread neuronal apoptosis in the brain, which was similar to the changes in the brains of infected immunocompetent C57BL/6J mice. These findings are consistent with the observations of

Theerasurakarn and Ubol (1998), who reported that the brains of adult mice immunosuppressed with cyclophosphamide showed marked apoptosis after intracerebral inoculation of CVS.

Peripheral inoculation of mice with the attenuated Pasteur virus strain of rabies virus (PV) is associated with T cell-dependent paralysis and neuronal apoptosis (Galelli *et al.*, 2000). In contrast, peripheral inoculation of the more neurovirulent CVS strain in either adult mice or bats causes severe and fatal clinical disease with little neuronal apoptosis (Reid and Jackson, 2001; Jackson, 2003). CVS is efficient in invading the CNS and in evading the host immune defenses, which is associated with destruction by apoptosis of CD3-positive T cells and limitation of the inflammation in the CNS (Baloul and Lafon, 2003). The neuronal apoptosis observed after intracerebral inoculation with CVS may be related to (1) high viral loads in infected neurons and perhaps direct virus-induced effects, (2) efficient stimulation of the innate immune response in the host, and/or (3) lack of neuroprotective stimulation that occurs after peripheral inoculation of CVS. The present study provides evidence that the adaptive immune response does not play a fundamental role in producing the neuronal apoptosis in this model, in contrast to the abortive rabies infection produced by peripheral inoculation of PV (Galelli *et al.*, 2000). The importance of neuronal apoptosis in producing the clinical neurological disease in this model of experimental rabies with intracerebral inoculation of CVS needs further study. An understanding of mechanisms involved in producing CVS-induced neuronal apoptosis may lead to the development of therapeutic interventions that will alter the course of fatal encephalomyelitis in this experimental model of rabies.

References

- Alcami A, Koszinowski UH (2000). Viral mechanisms of immune evasion. *Trends Microbiol* **8**: 410–418.
- Allsopp TE, Fazakerley JK (2000). Altruistic cell suicide and the specialized case of the virus-infected nervous system. *Trends Neurosci* **23**: 284–290.
- Baloul L, Lafon M (2003). Apoptosis and rabies virus neuroinvasion. *Biochimie* **85**: 777–788.
- Fazakerley JK, Allsopp TE (2001). Programmed cell death in virus infections of the nervous system. *Curr Top Microbiol Immunol* **253**: 95–119.
- Friedlander RM (2003). Apoptosis and caspases in neurodegenerative diseases. *N Engl J Med* **348**: 1365–1375.
- Galelli A, Baloul L, Lafon M (2000). Abortive rabies virus central nervous infection is controlled by T lymphocyte local recruitment and induction of apoptosis. *J Neuro Virol* **6**: 359–372.
- Griffin DE, Hardwick JM (1999). Perspective: virus infections and the death of neurons. *Trends Microbiol* **7**: 155–160.
- Jackson AC (2002a). Pathogenesis. In: *Rabies*. Jackson AC and Wunner WH (eds.), San Diego: Academic Press. pp 245–282.
- Jackson AC (2002b). Human disease. In: *Rabies*. Jackson AC and Wunner WH (eds.), San Diego: Academic Press. pp 219–244.
- Jackson AC (2003). Neuronal apoptosis in experimental rabies: role of the route of viral entry. *Neurology* **60**(Suppl 1): A102.
- Jackson AC, Park H (1998). Apoptotic cell death in experimental rabies in suckling mice. *Acta Neuropathol* **95**: 159–164.
- Jackson AC, Rossiter JP (1997). Apoptosis plays an important role in experimental rabies virus infection. *J Virol* **71**: 5603–5607.
- Jackson AC, Warrell MJ, Rupprecht CE, Ertl HCJ, Dietzschold B, O'Reilly M, Leach RP, Fu ZF, Wunner WH, Bleck TP, Wilde H (2003). Management of rabies in humans. *Clin Infect Dis* **36**: 60–63.
- Jackson AC, Ye H, Phelan CC, Ridaura-Sanz C, Zheng Q, Li Z, Wan X, Lopez-Corella E (1999). Extraneural organ involvement in human rabies. *Lab Invest* **79**: 945–951.
- Kassis R, Larrous F, Estaquier J, Bourhy H (2004). Lyssavirus matrix protein induces apoptosis by a TRAIL-dependent

- mechanism involving caspase-8 activation. *J Virol* **78**: 6543–6555.
- Mombaerts P, Iacomini J, Johnson RS, Herrup K, Tonegawa S, Papaioannou VE (1992). RAG-1-deficient mice have no mature B and T lymphocytes. *Cell* **68**: 869–877.
- Morimoto K, Hooper DC, Spitsin S, Koprowski H, Dietzschold B (1999). Pathogenicity of different rabies virus variants inversely correlates with apoptosis and rabies virus glycoprotein expression in infected primary neuron cultures. *J Virol* **73**: 510–518.
- Prehaud C, Lay S, Dietzschold B, Lafon M (2003). Glycoprotein of nonpathogenic rabies viruses is a key determinant of human cell apoptosis. *J Virol* **77**: 10537–10547.
- Reid JE, Jackson AC (2001). Experimental rabies virus infection in *Artibeus jamaicensis* bats with CVS-24 variants. *J NeuroVirol* **7**: 511–517.
- Rosner B. (1995). *Fundamentals of biostatistics*. Belmont, CA: Duxbury Press.
- Theerasurakarn S, Ubol S (1998). Apoptosis induction in brain during the fixed strain of rabies virus infection correlates with onset and severity of illness. *J NeuroVirol* **4**: 407–414.
- Thoulouze MI, Lafage M, Montano-Hirose JA, Lafon M (1997). Rabies virus infects mouse and human lymphocytes and induces apoptosis. *J Virol* **71**: 7372–7380.
- Thoulouze MI, Lafage M, Yuste VJ, Baloul L, Edelman L, Kroemer G, Israel N, Susin SA, Lafon M (2003). High level of Bcl-2 counteracts apoptosis mediated by a live rabies virus vaccine strain and induces long-term infection. *Virology* **314**: 549–561.
- Ubol S, Sukwattanapan C, Utaisincharoen P (1998). Rabies virus replication induces Bax-related, caspase dependent apoptosis in mouse neuroblastoma cells. *Virus Res* **56**: 207–215.